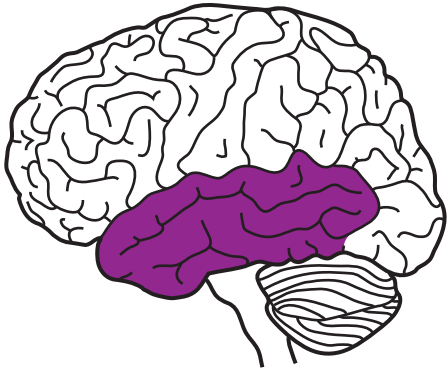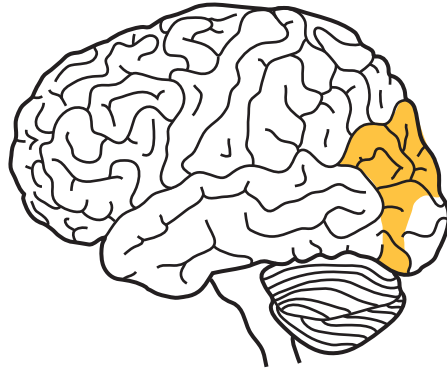
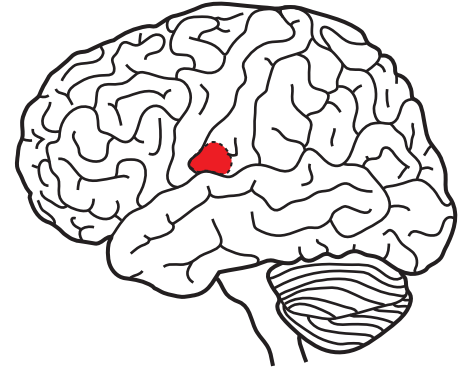




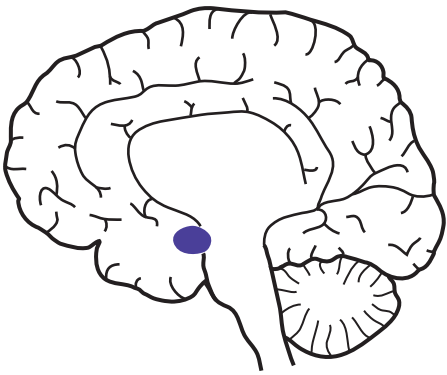
TEMPORAL LOBE



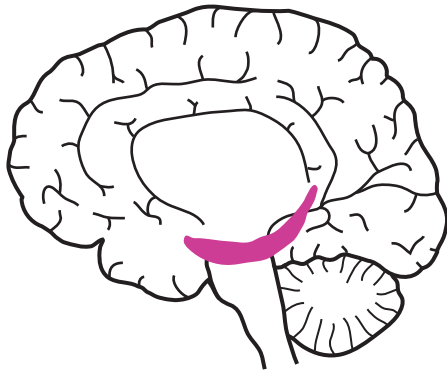
**VISUAL
ASSOCIATION AREA**



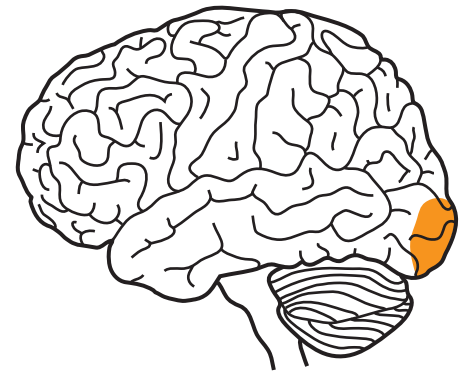
**VESTIBULAR
CORTEX**



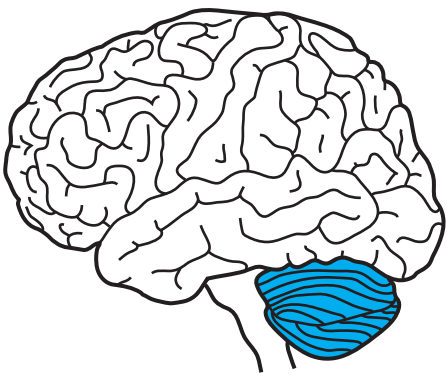
AMYGDALA



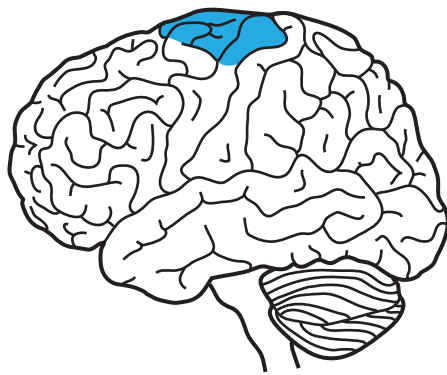
PARAHIPPOCAMPUS



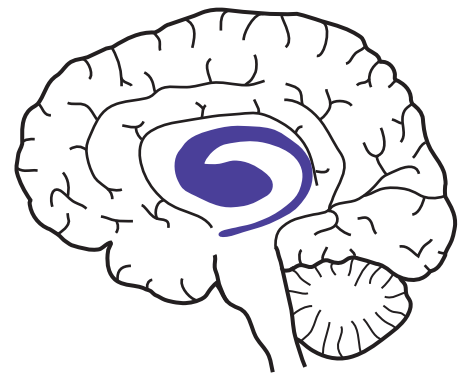
**VISUAL
CORTEX**



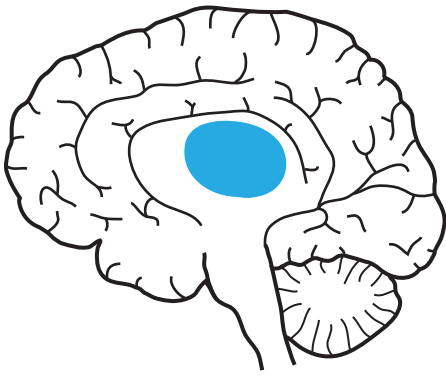
CEREBELLUM



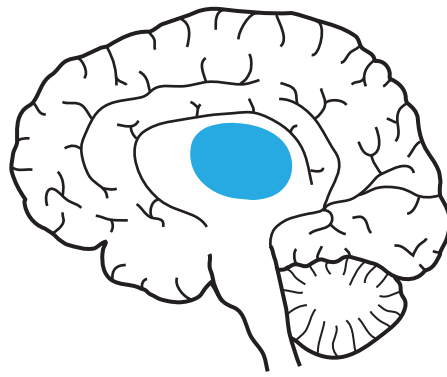
**SUPPLEMENTARY
MOTOR AREA**



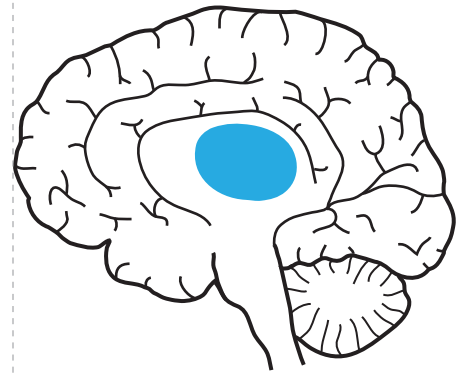
STRIATUM



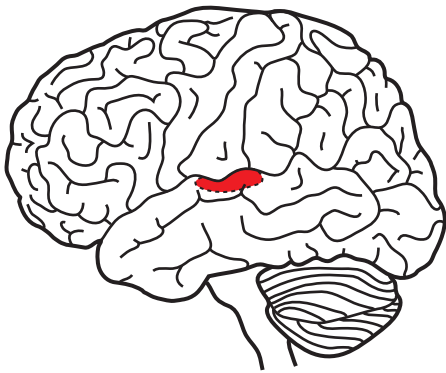
THALAMUS



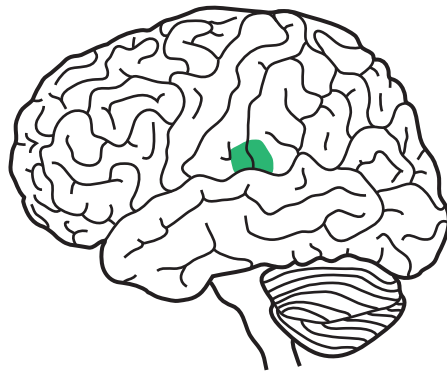
THALAMUS



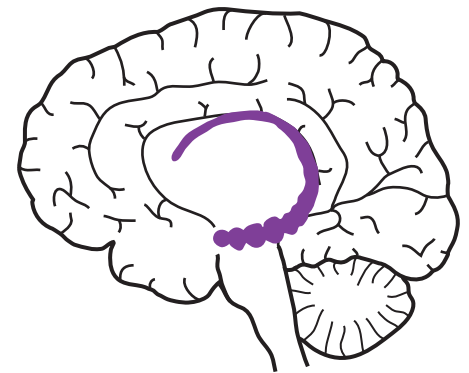THALAMUS



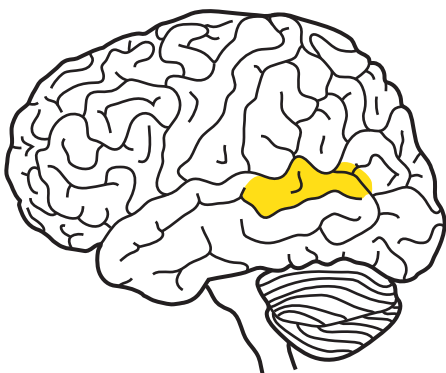
**AUDITORY
CORTEX**



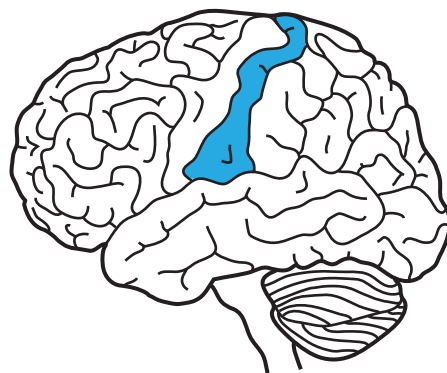
**GUSTATORY
CORTEX**



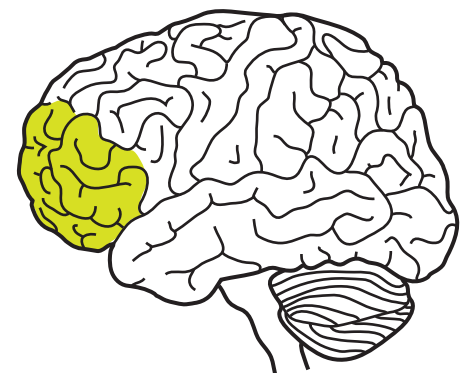
HIPPOCAMPUS



**WERNICKE'S
AREA**



**SOMATOSENSORY
CORTEX**



**PREFRONTAL
CORTEX**